

关节镜监视下微创治疗良性骨肿瘤

江长青, 张文涛[△], 肖德明, 李 伟, 张红雷, 杨 恒
(北京大学深圳医院运动医学与康复科, 广东深圳 518036)

[摘要] **目的** 探讨关节镜监视下微创局部切除良性骨肿瘤的效果。**方法** 2011年8月到2012年12月对8例良性骨肿瘤患者采用关节镜监视下微创治疗。其中骨软骨瘤3例,骨囊肿2例,非骨化性纤维瘤1例,骨样骨瘤2例。根据术前影像学资料定位,置入关节镜及刨刀进入病灶区,在关节镜监视下局部切除肿瘤,并用等离子刀处理切除肿瘤后创面,对存在骨缺损病例以同种异体骨充填。**结果** 8例患者术后恢复良好,入路切口小于3个,切口长度小于1.5 cm,其中2例充填同种异体骨。随访8~12个月,平均10个月,无复发、骨折及功能障碍;术后X线片显示病变切除彻底,骨缺损病灶同种异体骨充填完全。**结论** 深部骨良性肿瘤在关节镜监视下可以最大限度保留局部解剖结构。

[关键词] 骨肿瘤;良性;外科手术,微创性;关节镜

[中图分类号] R681.3

[文献标识码] A

[文章编号] 1671-8348(2015)12-1650-02

Arthroscopic minimally invasive surgery for treating benign bone tumor

Jiang Changqing, Zhang Wentao[△], Xiao Deming, Li Wei, Zhang Honglei, Yang Heng
(Department of Sports Medicine and Rehabilitation, Shenzhen Hospital of Peking University, Shenzhen, Guangdong 518036, China)

[Abstract] **Objective** To investigate the effect of arthroscopic minimally invasion for the local excision of benign bone tumor. **Methods** Eight patients with benign bone tumor from August 2011 to December 2012 were treated by arthroscopic minimally invasive operation, including 3 cases of osteochondroma, 2 cases of bone cyst, 1 case of non-ossifying fibroma and 2 cases of osteoid osteoma. The lesion location was determined by the preoperative imaging data, the arthroscope and plane cutter were placed into the lesion area the tumor was performed the local lesion resection under thearthroscopic monitoring, then the plasma was adopted to treat the resected wound surface of tumor, the bone defects were implanted by allogeneic bone. **Results** Eight cases were recovered well after operation. No postoperative complications were found. The approach incision <3 and the wound length <1.5 cm. Two cases were filled with allogeneic bone. There were no recurrence, fracture or dysfunction during the average follow up periods of 8-12 months. The postoperative X-ray showed that the lesion was completely resected and the bone defect lesion was completely filled with allogeneic bone. **Conclusion** The resection of deep benign bone tumor under the arthroscopic monitoring can maximize to retain the local anatomic structure.

[Key words] bone neoplasms; benign; surgical procedures, minimally invasive; arthroscope

对于四肢骨关节良性肿瘤目前临床多采用开放手术治疗,效果肯定,但创伤大,并发症多。随着关节镜技术在关节外应用的日益广泛,临床应用关节镜微创技术治疗骨关节良性肿瘤的报道逐年增多^[1-4]。本科自2011年8月到2012年12月对8例良性骨肿瘤患者采用关节镜监视下微创治疗,取得了良好疗效,现报道如下。

1 资料与方法

1.1 一般资料 选择2011年8月至2012年12月在本院采用关节镜监视下微创治疗的良性骨肿瘤患者8例,其中男5例,女3例;年龄23~56岁。8例患者中骨软骨瘤3例,骨囊肿2例,非骨化性纤维瘤1例,骨样骨瘤2例;部位:股骨3例,胫骨3例,肩胛骨2例。

1.2 方法

1.2.1 治疗方法 根据患者术前影像学资料定位,术前标记出肿瘤体表位置及周围解剖标记,于肿物标记位置两侧分别做两个小切口,直血管钳钝性分离,于肿块周围制备假性腔隙,置入关节镜及刨刀,在关节镜监视下清理肿瘤周围软组织,注意避开周围重要血管神经,显露骨肿瘤病灶后,用刮匙和磨钻彻

底切除肿瘤,并用等离子刀处理切除肿瘤后创面,对存在骨缺损病例以同种异体松质骨条充填,根据骨缺损大小,最少充填1包(5 mm×10 mm×10 mm),植骨最多充填3包(5 mm×10 mm×10 mm)。

1.2.2 术后处理 术后第1天患者即可下地负重活动或活动患肢,手术当天应用一线抗生素,如移植同种异体骨者术后再连续应用2 d抗生素,摄病变部位正侧位X线片,深部骨良性肿瘤给予三维CT复查。

2 结 果

2.1 治疗效果 8例患者术后恢复良好,入路切口小于3个,切口长度小于1.5 cm,其中2例充填同种异体骨。随访8~12个月,平均10个月,无复发、骨折及功能障碍;术后X线片显示病变切除彻底,骨缺损病灶同种异体骨充填完全。

2.2 典型病例 患者,女,26岁,右肩胛骨骨软骨瘤,病灶1.8 cm×2.9 cm,皮肤切口2个,长约1.0 cm。术中见病灶界限清楚,以骨刀和磨钻彻底切除肿瘤,切除物送病理,以等离子刀处理遗留骨性创面,术后3DCT片可见肿瘤切除彻底,随访10个月未见骨软骨瘤复发,见图1~4。

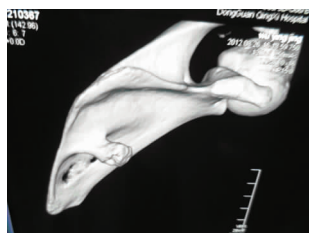


图 1 术前 3DCT 像

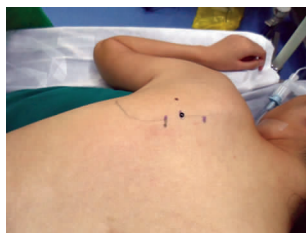

图 2 术中体位及入路

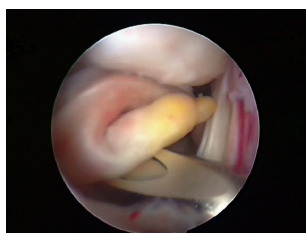


图 3 关节镜下见骨软骨瘤

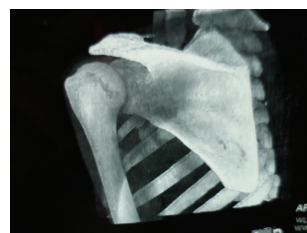


图 4 术后 3DCT 像

3 讨 论

对于良性骨肿瘤治疗既往采用开放手术局部切除和或植骨,疗效确定。但是术中为显示骨肿瘤,尤其深部骨肿瘤,须将周围正常的组织和解剖结构破坏,将损伤较多的组织,术后造成骨折、关节粘连和功能障碍等并发症^[5-6]。

良性骨肿瘤的病理形态长期稳定,很少发生转移和恶变。局部切除即可获得良好的治疗效果,因此采用微创技术局部切除良性骨肿瘤具有可行性。近年来,关节镜在透镜系统、光纤系统、小型化和辅助于器械方面的不断改进,关节镜外科在过去 10 年发展迅速,其对深部良性骨肿瘤切除的临床高准确性和低损伤性,改变了关节内及关节外疾病的诊断和治疗方法。有研究报道,关节镜下切除良性骨肿瘤,随访 1~2 年均未见复发,效果良好^[7-8]。关节镜技术在关节外的应用日益广泛,为微创治疗骨与关节良性肿瘤提供了新的方式,关节镜下完整切除良性骨肿瘤可行:(1)术前 CT 和 MRI 对其大小和边界有确切了解;(2)关节镜清晰度好、色彩真实、能分清肿物与正常组织的界限;(3)关节镜能观察到肿物的全貌,且视野良好^[9-10]。但必须严格手术适应证和禁忌证:(1)必须明确肿瘤的性质,对于具有恶变倾向、容易复发、肿瘤巨大且性质难以确定的肿瘤,为手术禁忌证^[11]。(2)术中如发现与术前诊断差异明显,须果断采用切开或其他手术方式。

近两年来,本科在关节镜监视下采用高速磨钻,射频刀等微创技术治疗骨与关节良性肿瘤取得了良好疗效。其中 1 例肩胛骨深面骨软骨瘤患者,既往手术方式须切断部分斜方肌及背阔肌,因部位深,显露困难,出血量多,操作困难,对患者损伤重;本研究采用关节镜技术直接观察病灶,能彻底切除肿瘤,精确性和安全性高、创伤小、病变切除准确。

本研究认为在关节镜下切除良性骨肿瘤可最大限度地减少深部组织创伤,操作安全、创伤小、避免了因显露病灶而造成的骨关节周围解剖结构和组织的广泛剥离造成的创伤,最大限度地保护了病灶周围的正常解剖结构与关节功能^[12]。另外,必须严格选择适应证,并非所有良性骨肿瘤都能采用关节镜微创治疗^[13-14],对于易复发或者具有恶变倾向的良性骨肿瘤则改用切开手术方法,决不能为追求微创导致巨创。

参考文献

[1] Mowafi H, Befaat H, Kotb S. Percutaneous destruction and alcoholisation for the management of osteoid osteoma [J]. Acta Orthop Belg, 2003, 6(9): 447-451.
 [2] 张羽飞,田孟强,王立德,等. 关节镜检查 and 镜下手术诊治膝关节内良性肿瘤[J]. 中国矫形外科杂志, 2008, 2008(11): 804-806.

[3] 纪经涛,胡永成. 骨样骨瘤的微创治疗[J]. 中华骨科杂志, 2008, 28(2): 163-166.
 [4] Gonöalves B, Schrödere S, Soltauet DW, et al. Arthroscopic resection of osteoid osteoma in the hip: a report of four patients and literature review[J]. In Current Orthopaedic Practice, 2010, 21(3): 320-326.
 [5] David P, Legname M, Dupond M. Arthroscopic removal of an osteoid osteoma of the talar neck[J]. Orthop Traumatol Surg Res, 2009, 95(6): 454-457.
 [6] Allagui M, Bauer T, Rousselin B, et al. Double localization of an osteoid osteoma of the ankle: percutaneous treatment by CT-guided drilling[J]. Rev Chir Orthop Reparatrice Appar Mot, 2007, 93(5): 506-510.
 [7] Westendorf C, Hoffmann J, Troitzsch D, et al. Ossifying fibroma of the skull: interactive image-guided minimally invasive localization and resection[J]. J Craniofac Surg, 2004, 15(5): 854-858.
 [8] Wiedemayer H, Sandalcioglu IE, Wiedemayer H, et al. The supraorbital keyhole approach via an eyebrow incision for resection of tumors around the sella and the anterior skull base [J]. Minim Invasive Neurosurg, 2004, 47(4): 221-225.
 [9] 倪磊,吕厚山,杜莉如. 膝关节内肿物的关节镜检查 and 手术[J]. 中华骨科杂志, 2001, 21(10): 601-604.
 [10] Rubin BP. Tenosynovial giant cell tumor and pigmented villonodular synovitis: a proposal for unification of these clinically distinct but histologically and genetically identical lesions[J]. Skeletal Radiol, 2007, 36(4): 267-268.
 [11] Kim JI, Kwon JH, Park YJ, et al. Arthroscopic excision of solitary intra-articular osteochondroma of the knee [J]. Knee Surg Relat Res, 2013, 25(1): 36-39.
 [12] Masoud MA, Said HG. Intra-articular hip injection using anatomical surface landmarks [J]. Arthrosc Tech, 2013, 2(2): e147-149.
 [13] Bahamondel L, Catalan J. Bone tumors around the knee: risk and benefits of arthroscopic procedure [J]. Arthroscopy, 2006, 22(5): 558-564.
 [14] Aalderink K, Wolf B. Scapular osteochondroma treated with arthroscopic excision using prone positioning [J]. Am J Orthop, 2010, 39(2): 11-14.

(收稿日期: 2014-10-28 修回日期: 2015-02-10)